


# Pacient č. 2

## Muž nar. 1990

Pracovní skupina pro IBD

Milan Lukáš



## Male, born 1990

- 2005 – massive GI bleeding (melena)
- 2006 – recurrent bleeding, antral and pyloric ulcerations proved and stomach surgery performed; Bilroth II stomach resection and gastro-jejuno-anastomosis with splenectomy and subfrenic abscess formation (surgery complications)
- 2007 – abdominal pain - daily basis, body weight lost (-4 kg)
- 2009 – massive GI bleeding ulceration in the stomach stamp and in anastomosis proved, the second surgery was indicated
- 2009 – subtotal gastrectomy and Y-gastro-enteroanastomosis sec- Roux performed



## Male, born 1990

- 2011 abdominal pain, body weight lost
- 2011 gastroscopy prove dlarge ulceration in the anastomosis and efferent small bowel loop
- Colonoscopy with normal finding including normal terminal ileum
- CRP in the normal range, but deep sideropenic anemia
- Capsule endoscopy was done – proved multiple large and small ulceration in the proximal part of the small bowel

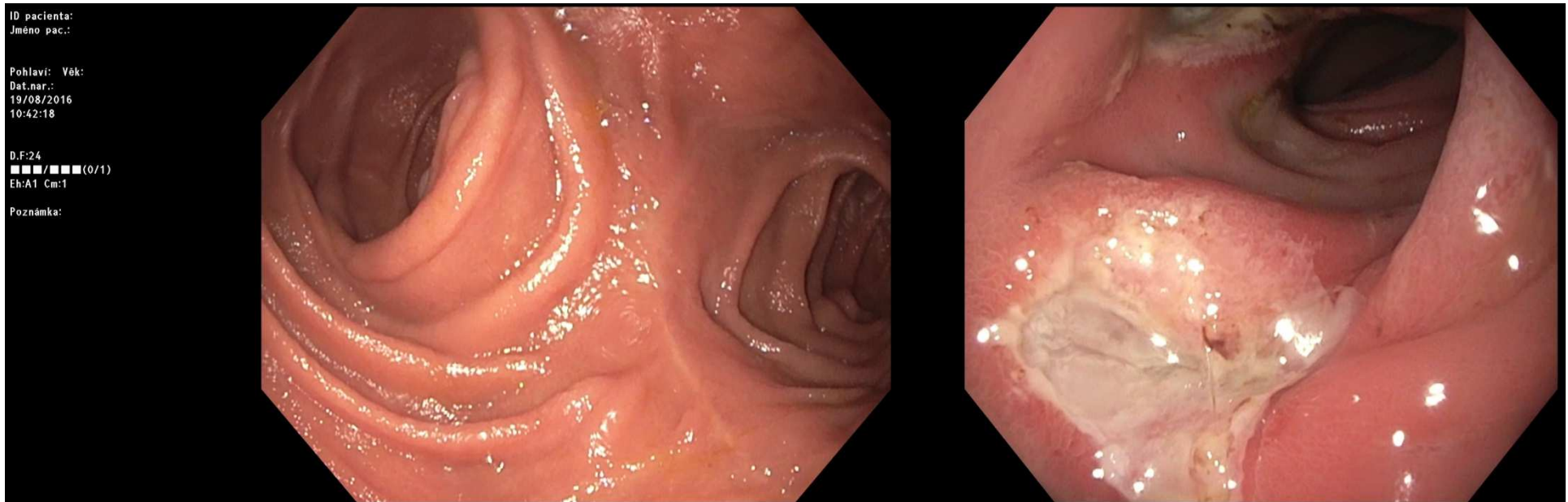
## Male, born 1990

- IBD diagnosed and azathioprine started -150 mg /daily + mesalazine 4g daily + PPI 40 mg daily, iron supplementation, despite - anemia, fatigue, intermitently abdominal pain
- he interrupted „ice hockey player“ carrier because disability
- 2015-2016 – frequent abdominal pain, body weight lost -16 kg/6 months, frequent vomitig after the meal



# Male, born 1990

- Gastroscopy, august 2016

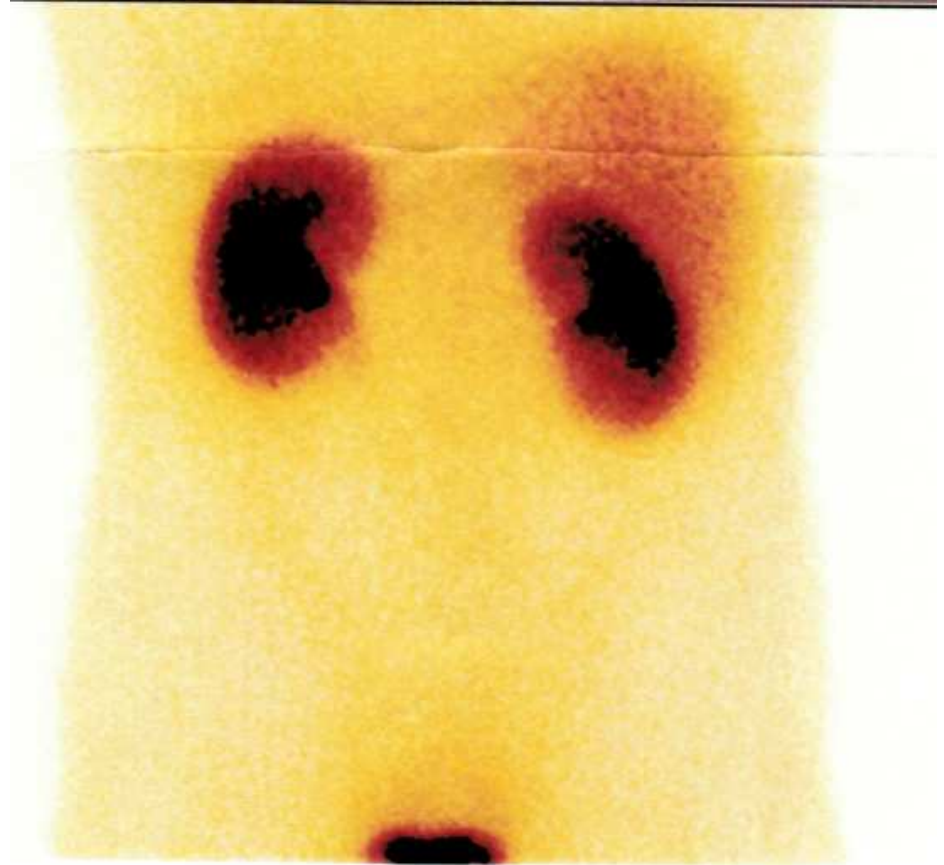
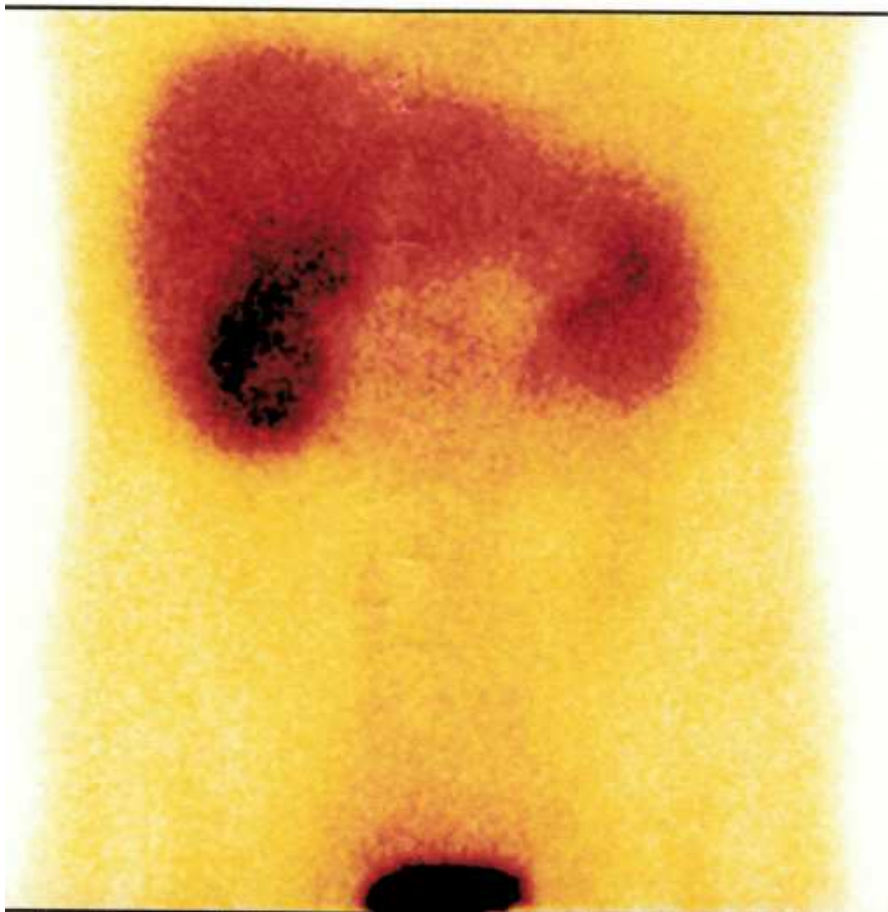


# What is your suggestion about the next proceeding and therapy?

- a) Crohn's disease involving the upper GIT biologic therapy with anti-TNF inhibitors is necessary
- b) Crohn's disease involving the upper GIT new biologic therapy with anti-integrins is necessary
- c) There is no IBD but vasculitis involving GIT, the next investigation e.g. CT angiography and robust corticosteroid therapy is necessary
- d) There is no IBD but Zollinger and Ellison syndrome, the next investigation e.g. octreoscan and gastrin serum level are necessary and huge dose of PPI are required



# OctreoScan 10-11.10.2016



# Průběh nemoci

- Zavedena terapie 90 mg Pantoprazolu
- Nemá žádné obtíže
- Přibral 12 kg/za 3 měsíce na tělesné váze



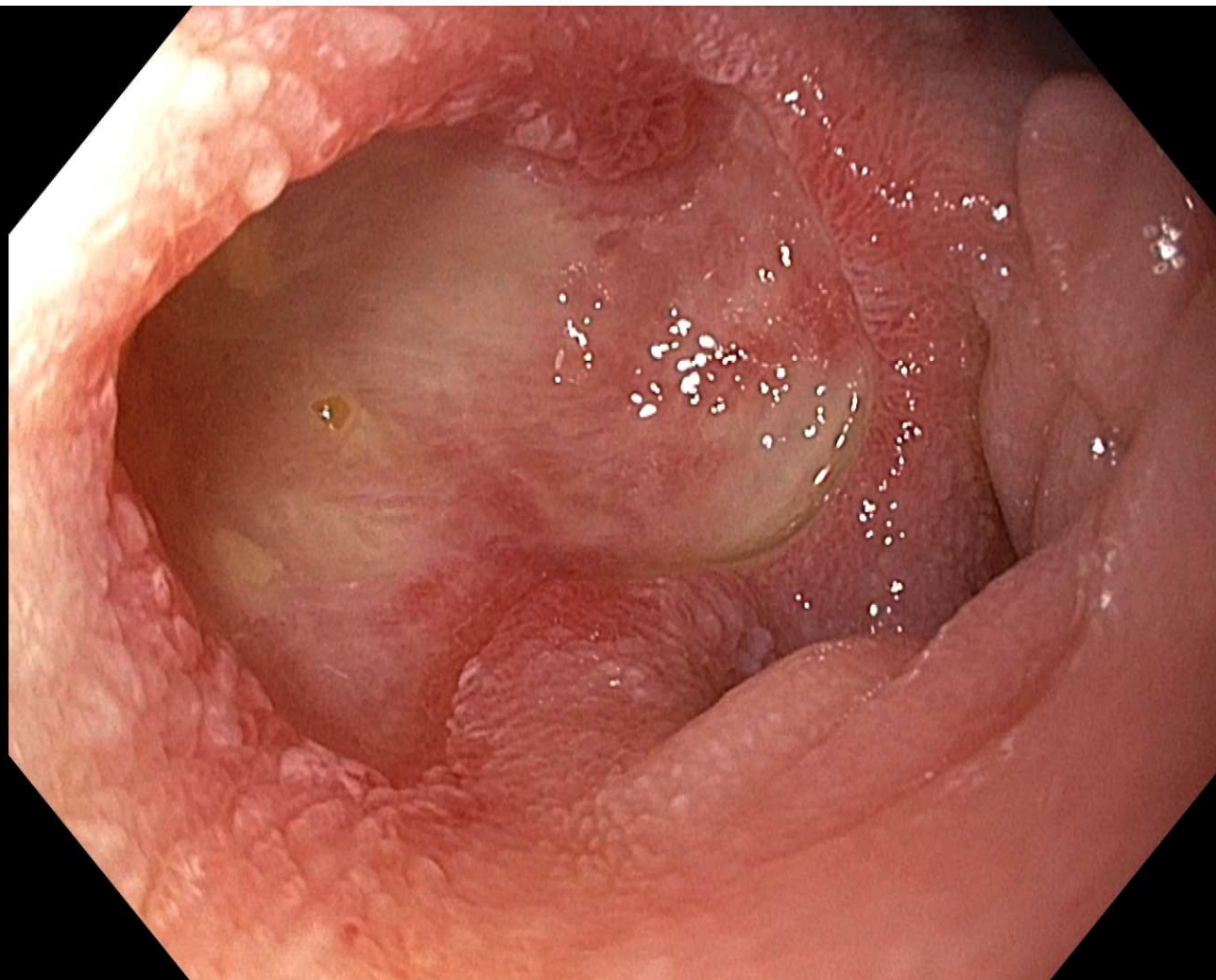
# 28.5.2018 terapie Esomeprazol 80mg denně

ID pacienta:  
Jméno pac.:

Pohlaví: Věk:  
Dat.nar.:  
23/05/2018  
10:25:28

D.F:30  
■ ■ □ / --- (0/5)  
Eh:A3 Cm:1

Poznámka:



# 28.5.2018 terapie Esomeprazol 80mg denně

ID pacienta:

Jméno pac.:

Pohlaví: Věk:

Dat.nar.:

23/05/2018

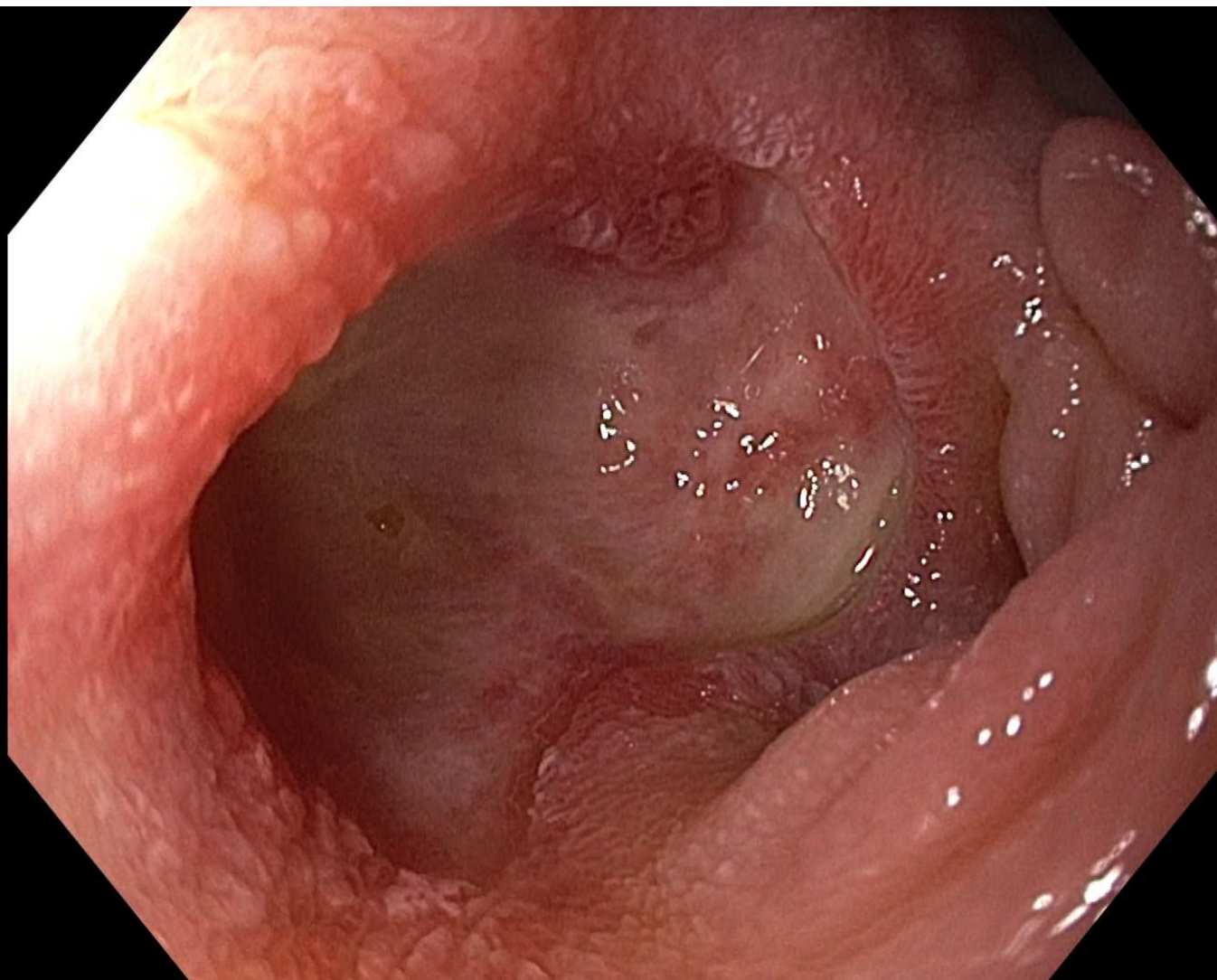
10:25:32

D.F:31

■ ■ □ / --- (0/6)

Eh:A3 Cm:1

Poznámka:



# 28.5.2018 terapie Esomeprazol 80mg denně

ID pacienta:

Jméno pac.:

Pohlaví: Věk:

Dat.nar.:

23/05/2018

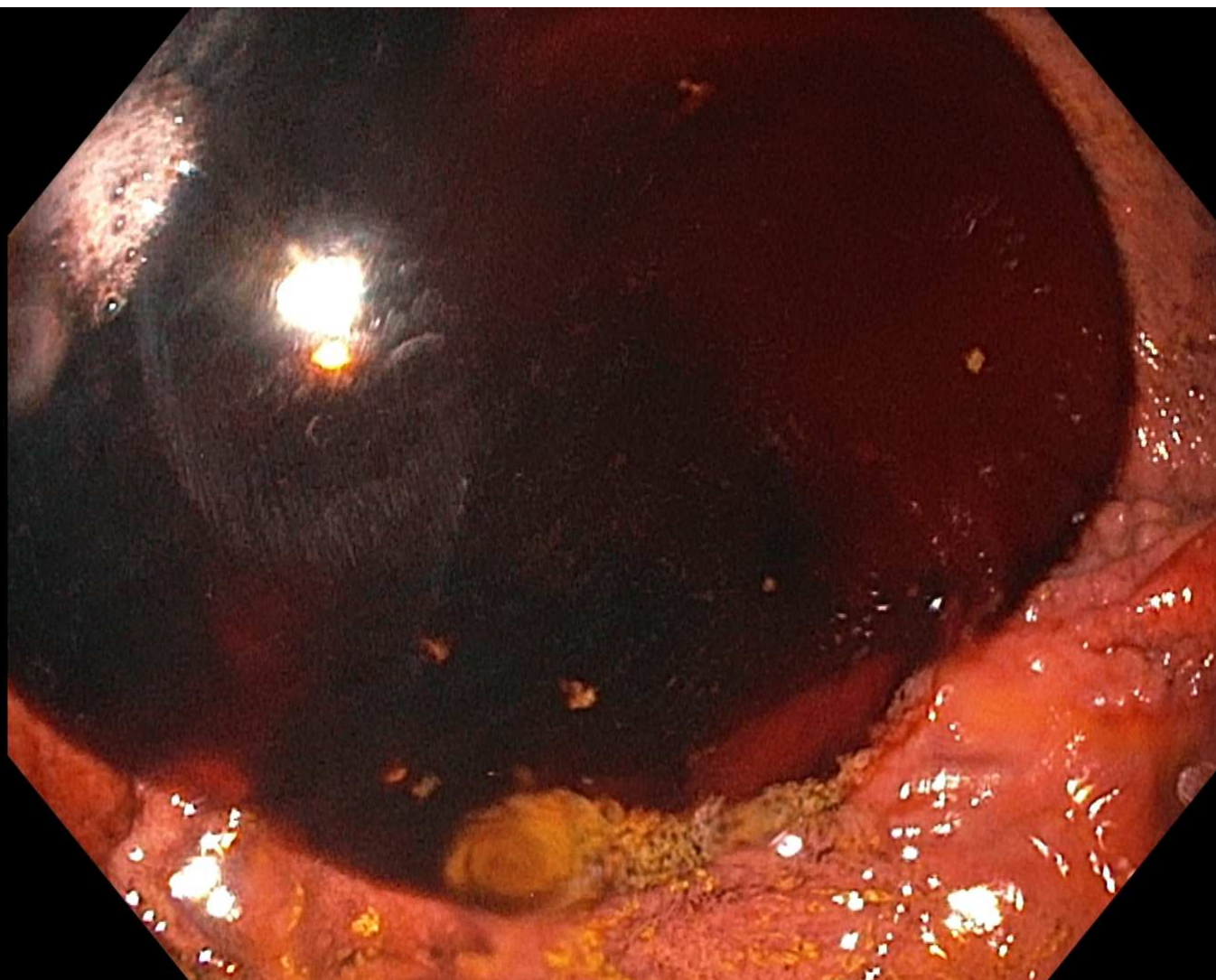
10:30:57

D.F:33

■ ■ □ / --- (0/8)

Eh:A3 Cm:1

Poznámka:



## Další postup ?

- Medikamentózní léčba IPP i.v. + somatostatinový analog ?
- Chirurgická intervence ?
  - totální gastrektomie
  - odstranění „retinovaného antra“ nebo ektopického ložiska produkující gastrin